



CORE-INFO:

Oral injuries and bites on children

This leaflet summarises what is currently known about oral injuries and human bites in relation to child abuse. The information will be of particular interest to dentists, dental care professionals, paediatricians, and A&E staff. The leaflet will also be relevant to nursery nurses, health visitors, school nurses, teachers, legal practitioners, social workers and the police. It is based on systematic reviews of all the quality work in the world literature about oral injuries and bites on children; full details are available at: www.core-info.cardiff.ac.uk

Oral injuries

What do we know about injuries to the mouth?

As many as 50 per cent of children sustain an injury to the mouth by the time they leave school. Most of these are accidental and, in older children, often caused by falls and sporting accidents. In cases of physical abuse, the head and face are the areas of the body most commonly injured. Injuries to the lips are the commonest recorded abusive injury to the mouth. These are either cuts or bruises. However, all areas of the mouth can be injured in physical abuse: teeth may be displaced or broken and there may be cuts, abrasions or bruises to the inside of the lips, the roof of the mouth, the tongue or the lingual frenum (underneath the tongue). Injuries to the mouth, including the teeth, can cause considerable pain and discomfort and, if left untreated, may well affect a child's appetite and growth.

How can you tell there has been an injury to the mouth?

Unless you are a dentist it is very difficult to tell. However, a child may complain of a pain in their mouth or have difficulty eating, or you may notice that the teeth are discoloured (brown or grey), which may mean that there is an old injury. A broken tooth may be recognised only because of a subtle grey discolouration. Abusive injuries to the mouth are not always obvious and, unless a child says they have been abused, or there are other unexplained injuries, may only come to light if you notice that permanent teeth are inexplicably missing.

Is a torn labial frenum diagnostic of physical child abuse?

The labial frenum is the fold of tissue inside the mouth that joins the upper or lower lip to the gums. For a long time practitioners have believed that injury to the upper labial frenum is diagnostic of physical abuse.

In the scientific literature there are fewer than 50 recorded cases of an abusive torn labial frenum in children. When present in an abused child, they are frequently associated with multiple injuries and many of these children died from the assault. Most were under five years old. However, a torn frenum can also occur accidentally if a toddler or young child falls on their face, catches their mouth on low-level furniture or receives an accidental blow to the face – for example by a swing. There is not enough evidence in the literature to support the view that a torn labial frenum in isolation is diagnostic of child abuse. Any injury of this type must be assessed in the context of the explanation given, the child's developmental stage and a full examination. If it remains unexplained in a child under two years, assessment would include a full skeletal survey and consideration of other investigations, as appropriate.

What should a dental professional do if they suspect a child has been abused?

The General Dental Council (GDC) makes it absolutely clear that dental professionals, in common with all those who work with children, have a responsibility to know the local child protection procedures and to follow them if they suspect a child may be at risk because of abuse or neglect. Further information and guidance about the responsibilities of dentists has been published in a handbook, Child Protection and the Dental Team: an introduction to safeguarding children in dental practice. This educational resource is available at: www.cpdt.org.uk

What should a paediatrician do if they suspect a child has been abused?

If a paediatrician suspects a child of being abused, a routine examination of the child's mouth and teeth should always be carried out. Paediatricians therefore need an understanding of the basic dentition of children at different ages and stages of development, and should seek a dental opinion if there are concerns.

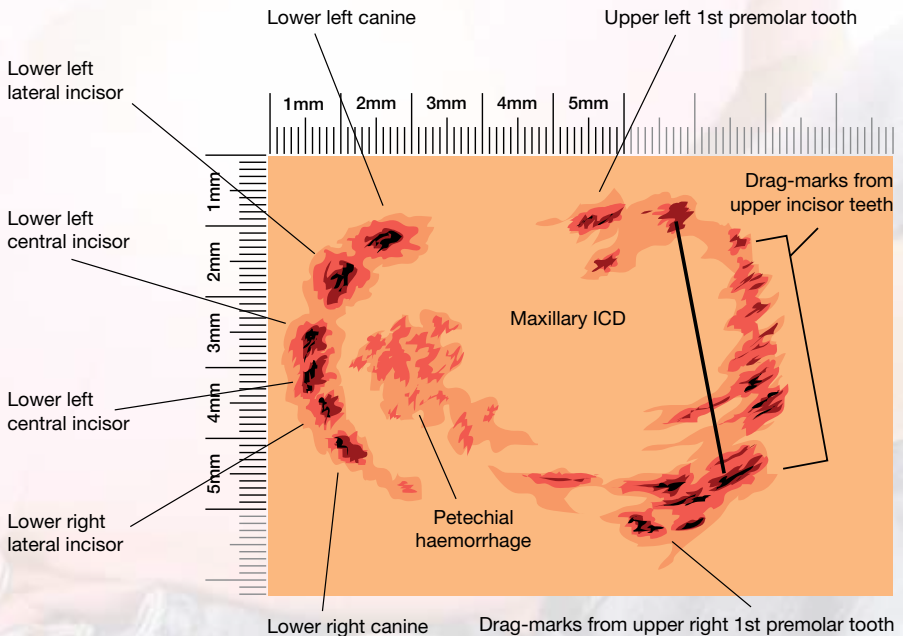
Bites

How common are injuries caused by bites?

Bites are a relatively common injury in children. Approximately one per cent of all A&E attendances are due to bites, and around one in 600 children attending A&E have been bitten. When an adult bites a child sufficiently hard to leave a mark, it is an assault. An adult bite on a child is the only physical injury where there is the potential to identify exactly who has attacked the child.

What do injuries caused by bites look like?

A bite leaves an oval or circular mark, consisting of two symmetrical, opposing, u-shaped arches separated at their base by an open space. The arcs may include puncture wounds, indentations or bruising from the marks of individual teeth. These marks are what make bites unique.



A bite may be confused with other skin disorders – such as ringworm, drug reaction, *pityriasis rosea*. However, there is no scaling of the skin in a bite, as there is in some of these conditions, and most skin disorders will be spread over the body or have other symptoms associated with them.

Distinguishing children's bites from adults' bites

Children often bite one another and they may also be bitten by animals. The challenge, therefore, is to recognise when an injury is a human bite and whether it was caused by an adult. If an adult bite is suspected, practitioners should always follow their organisation's safeguarding procedures by reporting their concerns to the designated person for child protection.

A forensic dentist should also be consulted for an opinion as to whether the lesion is consistent with an adult or child, and whether there are characteristics to determine who bit the child. The British Association for Forensic Odontology have published guidelines about the gap between the eye teeth in the upper jaw that will distinguish adult from child bites, and this is a standard measurement that is made. However, this requires clinical expertise to interpret. There is no specific validation of these measurements in the literature; they are based on knowledge of normal dental anatomy – details can be found at: www.bafo.org.uk

Distinguishing human bites from animal bites

Dogs and other carnivores (such as ferrets or rats) tend to tear the skin and leave deep puncture wounds. These are also much narrower bites than human ones.

What should a paediatrician do if they suspect a child has sustained a human bite?

Any human bite could be abusive and should be fully assessed, ideally by a forensic dentist (see www.bafo.co.uk). Forensic dentists potentially play an important part in the child protection process. If involved early enough, they can take serial photographs and casts of the bite, and possibly retrieve DNA, which can help identify the perpetrator.

If a doctor or dentist is unable to make immediate contact with a forensic dentist, they should first measure and record the intercanine distance, then obtain photographs of the suspected bite. The photographic record must include one plain image and a second image that includes a right-angled measuring device beside the mark. If the bite is on a curved surface – such as the arm – then the image with the measuring device should be recorded in each plane. A forensic dentist should still be consulted at the earliest opportunity. Washing around the area of the bite should be avoided as it may be possible to obtain the perpetrator's DNA from the injury. If there is going to be a delay in getting a specialist opinion, it may be valuable to repeat the photographs after one or two days, as with less swelling the individual marks from each tooth may be clearer.

Further support from the NSPCC

If you are worried about a child, the NSPCC is here to help, 24 hours a day, seven days a week, free of charge.

Phone 0808 800 5000

Email help@nspcc.org.uk

Text 88858 (Text 07786 200001 in Channel Islands, standard call rates apply)

Or visit www.nspcc.org.uk/help

NSPCC's information service

The NSPCC's library is the most comprehensive collection of specialist resources relating to child protection in the UK. It contains over 40,000 records and you can access it online at **www.nspcc.org.uk/inform**

You can also subscribe to CASPAR, a news service that signposts you to the latest policy, practice, and research in child protection.

Sign up at www.nspcc.org.uk/inform

To download this leaflet for free, or for printed copies of this leaflet, please go to **www.nspcc.org.uk/core-info** for price details.

Systematic review updated June 2012.

Core-info leaflet updated November 2012.

For the most up to date information on this review and the project's other systematic reviews visit the Core info website **www.core-info.cardiff.ac.uk**

Further details of this review can be found by scanning the QR code below.

This is a collaborative project between the Early Years Research Programme, Cochrane Institute of Primary Care & Public Health, School of Medicine, Cardiff University and the NSPCC.

